



Patient

NHS No

D.O.B.

Patient Ref

Reason

Claudication

Outcome

disease severe, Obscured, Poor images, Calcified

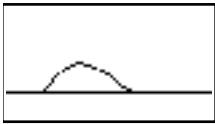
Right

190

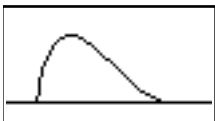
1.00



Good



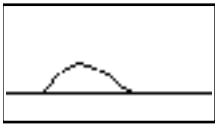
Weak



Weak



Absent



Weak/Absent

Brachial

Common Femoral

High Thigh

Low Thigh

Popliteal

High Calf

Peroneal

Anterior Tibial

Posterior Tibial

Dorsalis Pedis

Toe Pressure

Post Exercise

Left

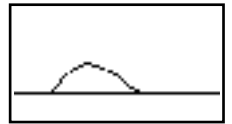
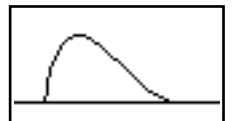
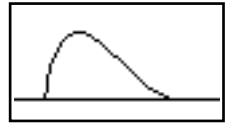
Good

Reduced

Reduced

Absent

Weak/Absent



Notes

BILATERAL LOWER LIMB ARTERIAL DUPLEX.

Aorta is patent 117cm/s triphasic with mild disease and is of normal calibre - 1.4cm.

RIGHT: Common and external iliac arteries are patent with mild diffuse disease, bi/triphasic waveforms, PSV 149 and 112cm/s, respectively.

CFA has mild-mod disease 166cm/s turbulent triphasic.

PFA origin has mild disease 74cm/s triphasic.

SFA origin has mild disease 57cm/s just triphasic. Vessel then becomes moderately to heavily diseased

Assessed by

Lukasz Koprowski

Checked by



Patient

NHS No

D.O.B.

Patient Ref

through the proximal to mid thigh with maximum PSV increasing from 121-413cm/s, turbulent monophasic waveforms. The mid to distal SFA was very difficult to track, with large collaterals seen within the area ?patency. Where visualised, the flow is monophasic, PSV 36cm/s.

Proximal popliteal contained poor flow ?patency. The vessel becomes patent in the mid section via the collateral. Mid-distal section is mildly diseased, monophasic waveforms, PSV 52cm/s. TPT appears patent with 2 vessel run-off seen.

Poor flow within the PTA ?patency. Some weak monophasic flow noted at mid calf, PSV 20cm/s.

Peroneal is patent where seen 45cm/s monophasic.

No colour flow detected within the ATA, which is calcified ?patency ?occluded.

LEFT: CIA and EIA - moderate disease, good triphasic waveforms, PSV ranging from 104cm/s to 126cm/s.

CFA - mild disease, slightly turbulent triphasic waveforms, PSV 134cm/s. Focal moderate disease noted in the distal vessel, turbulent triphasic waveforms, PSV 205cm/s.

PFA (origin) - mild disease, turbulent triphasic waveforms, PSV 194cm/s.

SFA - heavily diseased/calcified throughout, multiple obscured regions with intermittent areas of flow along length - ?multiple moderate focal stenosis, mono/triphasic waveforms throughout. Severe, focal disease noted in the proximal thigh at ~66cm prox to MM (~1.3cm), PSV 458cm/s turbulent monophasic. The remainder of the vessel has PSV ranging from 110-76cm/s monophasic.

POPA - slightly irregular dense and calcified plaque identified in the proximal vessel, but no significantly raised velocities noted at this time, PSV 83cm/s monophasic waveforms. Distal POPA and TPT appear patent and moderately diseased; origins of at least 2 vessel run-off noted.

ATA - unable to identify flow in the calcified vessel ?patency ?occluded.

PTA - some flow seen in the mid calf, monophasic waveforms PSV 19cm/s, but unable to identify flow in the proximal and distal calf.

PEROA - appears patent, monophasic waveforms, PSV 58cm/s at the ankle.

Unable to assess bilateral, resting pressure ratios due to weak crural signals.

Patient

NHS No

D.O.B.

Patient Ref

